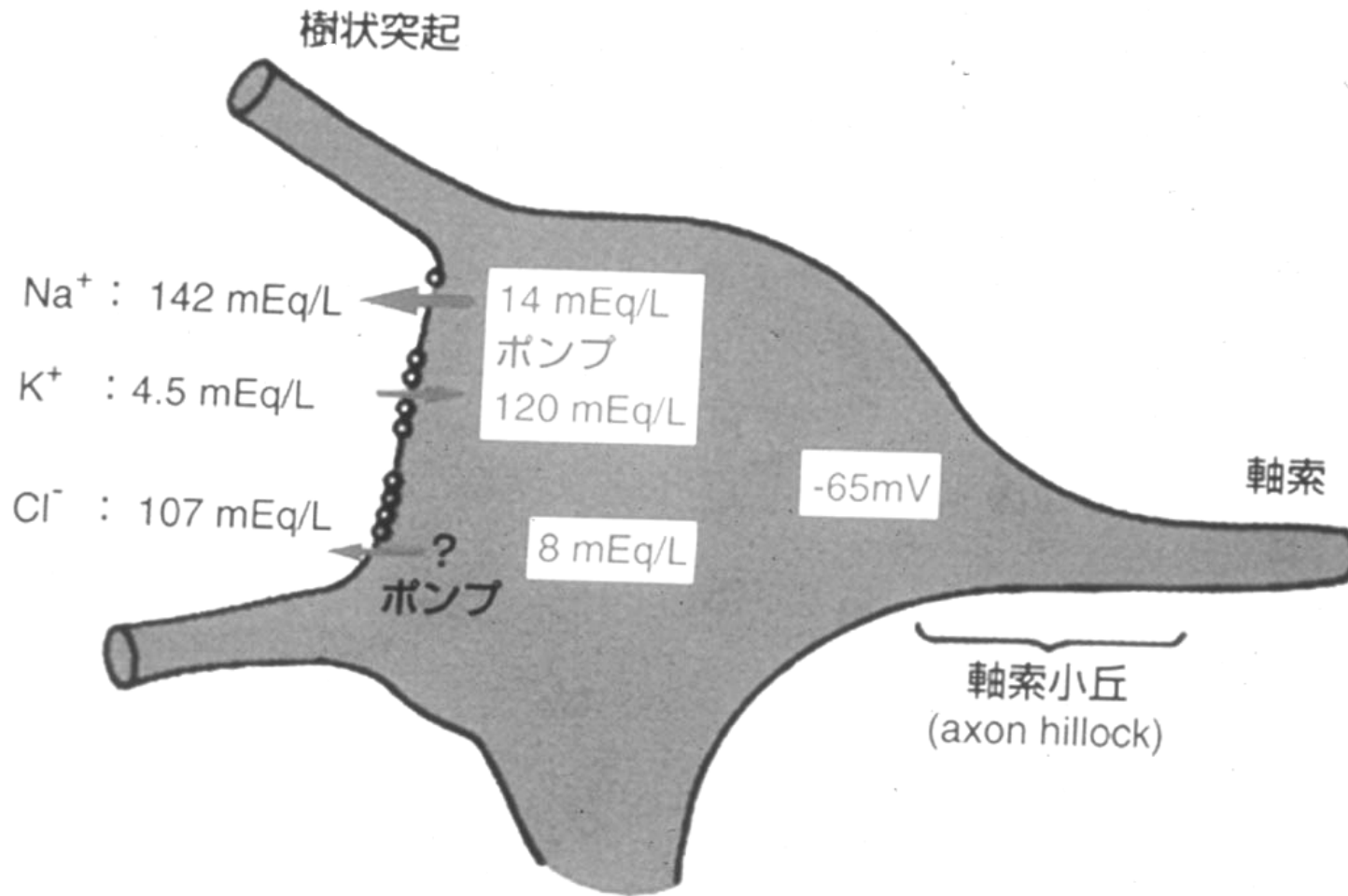
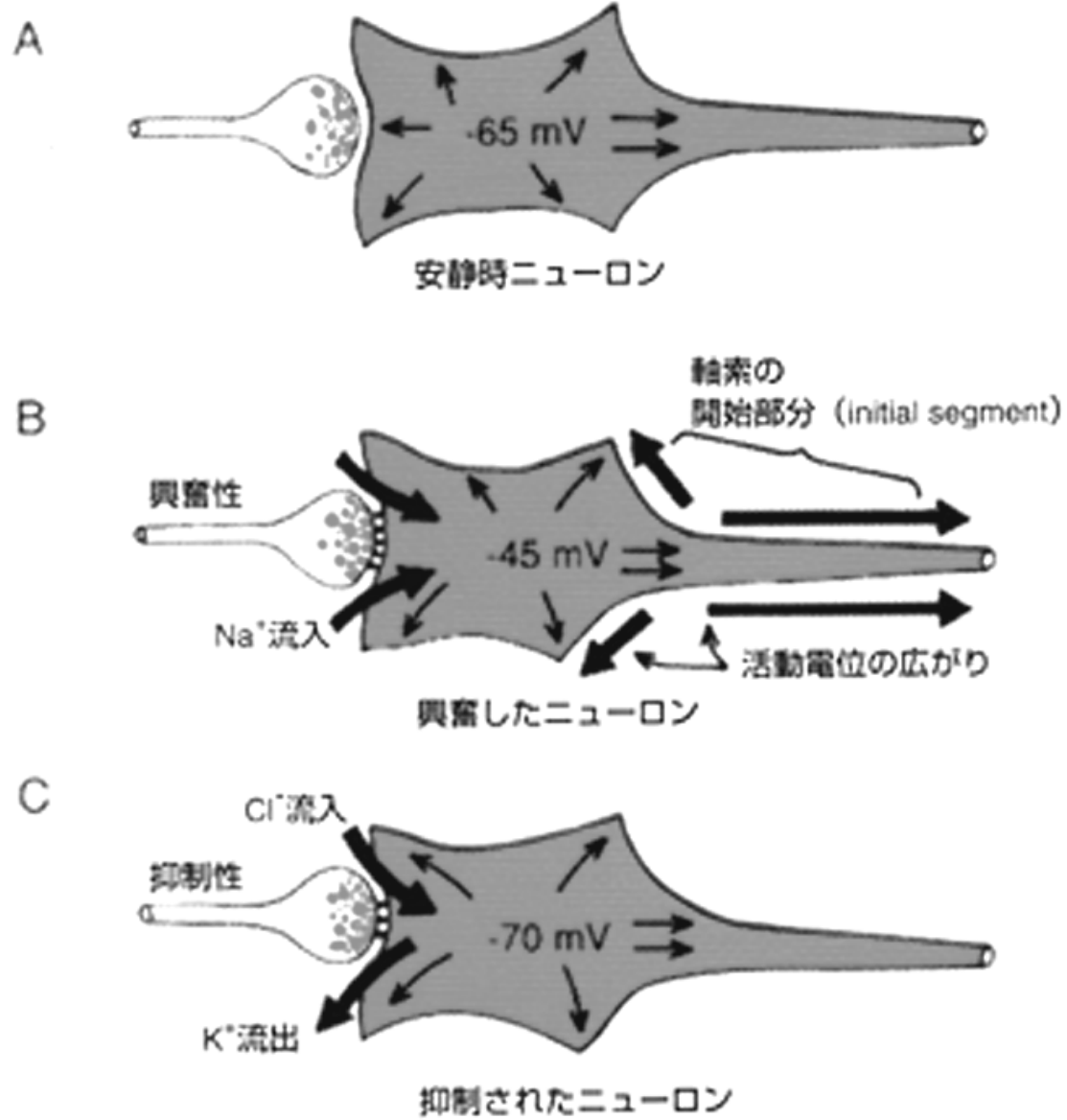
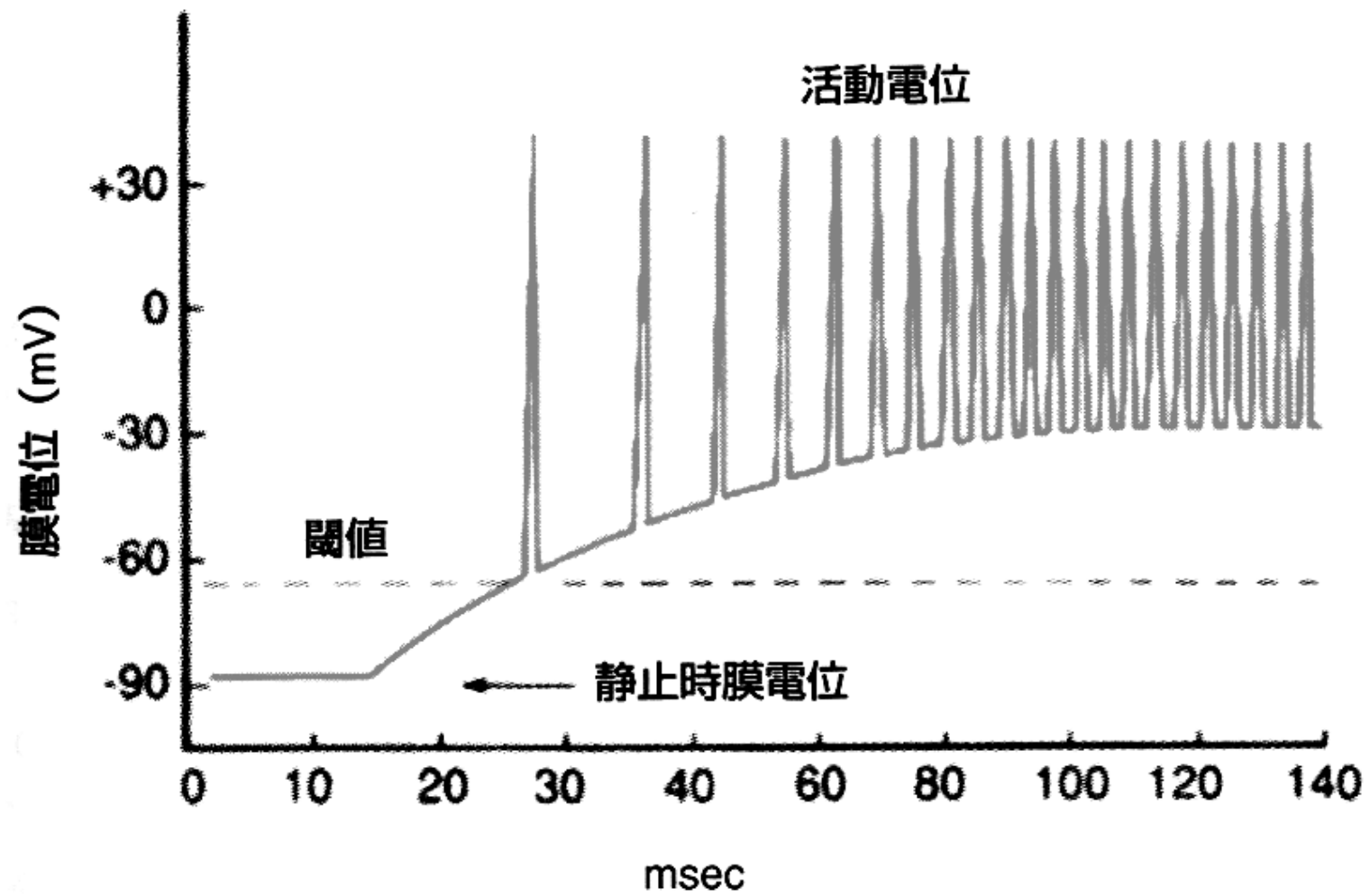
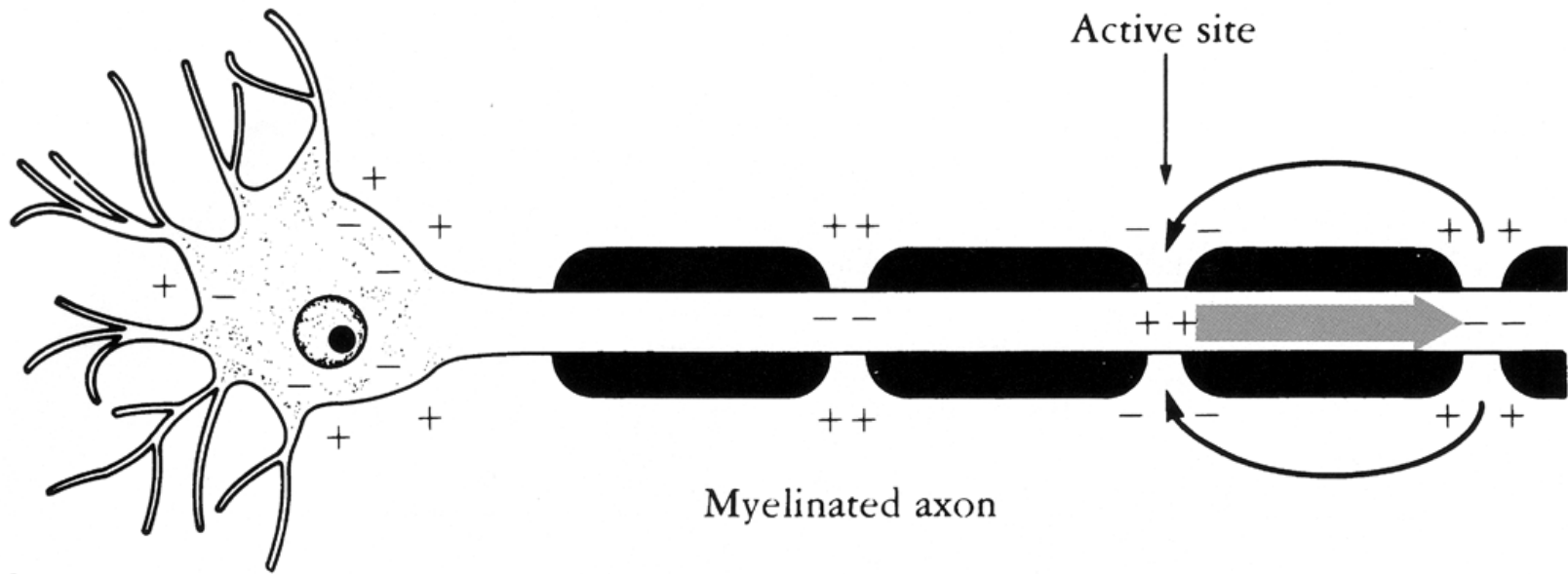


興奮性膜

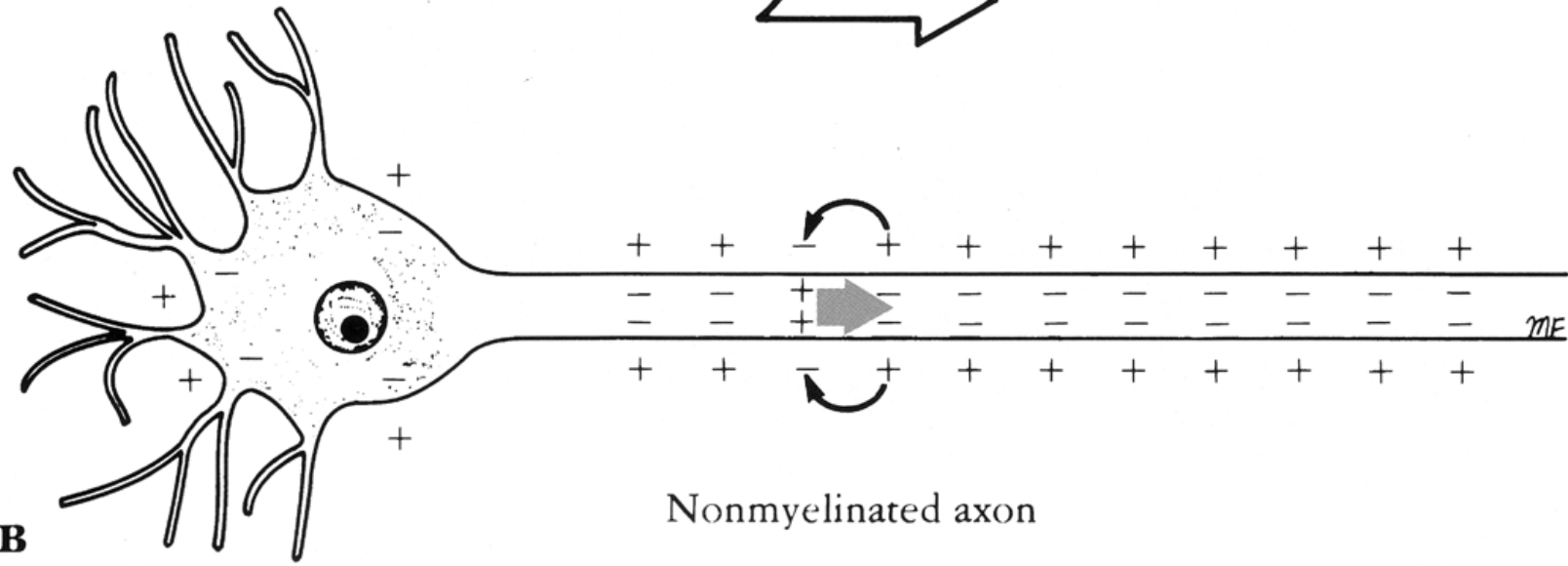
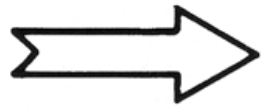




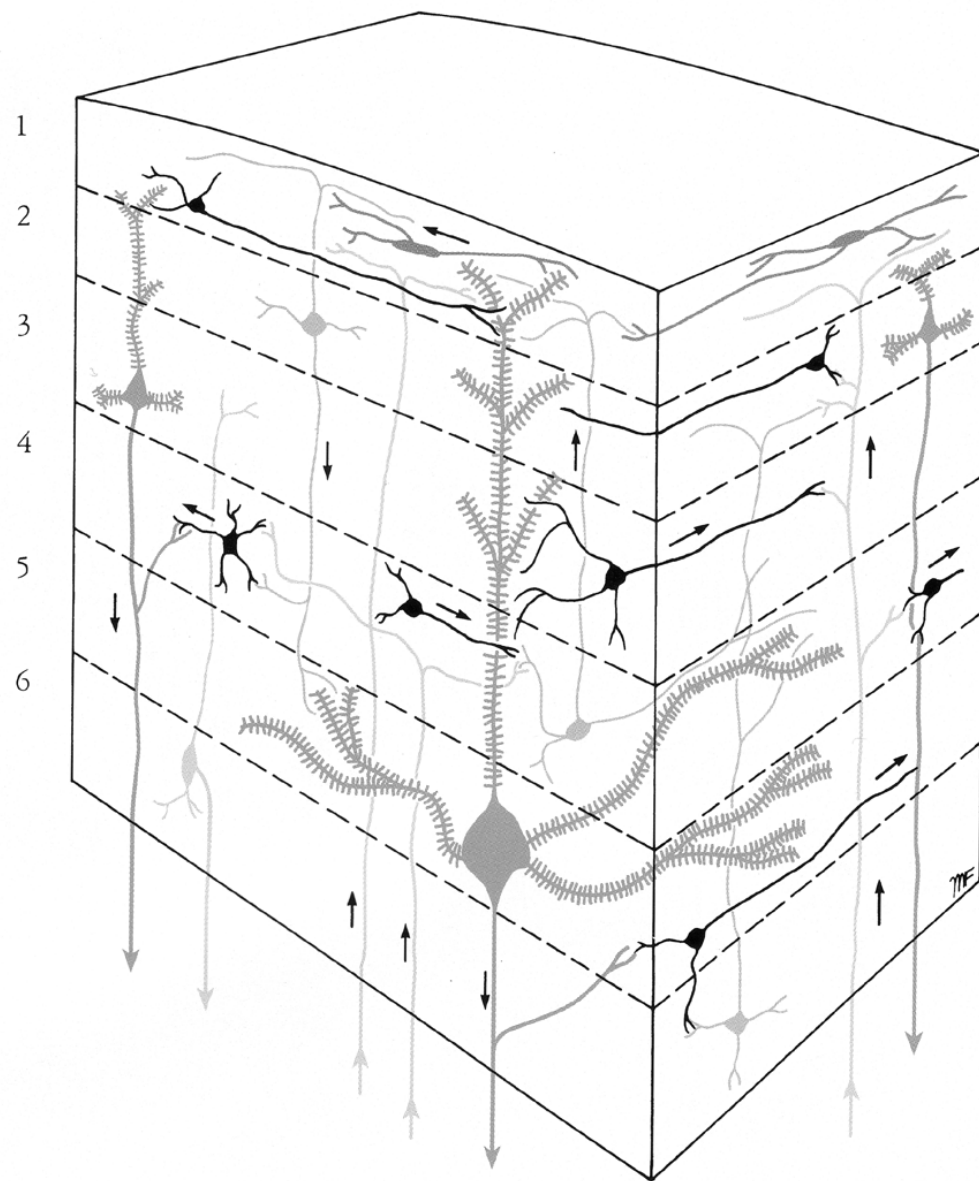




A

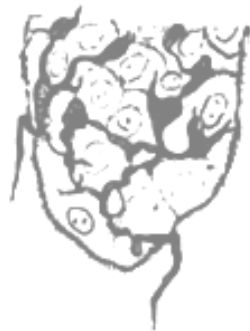

B





自由神経終末



拡張先端受容器



触感毛



パチニ小体



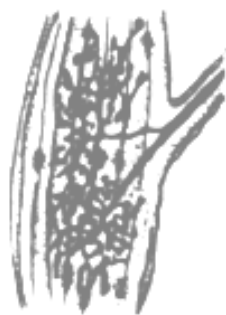マイスナー小体



クラウゼ小体



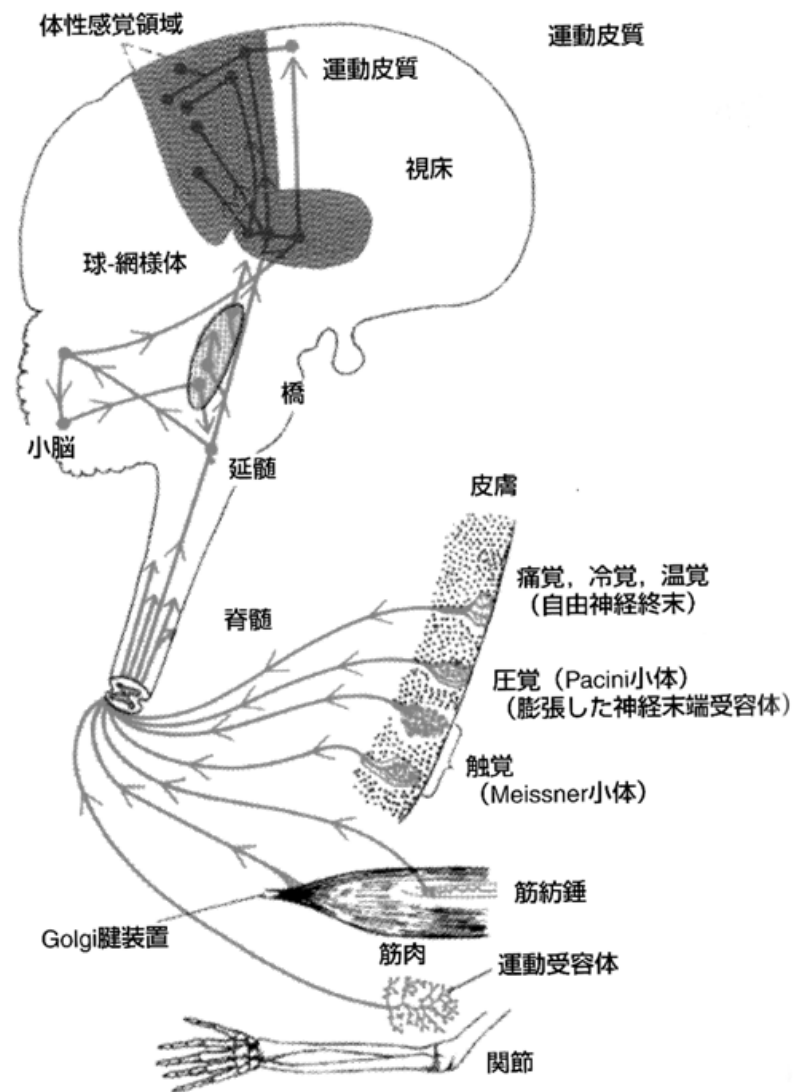
ルフィニ終末器

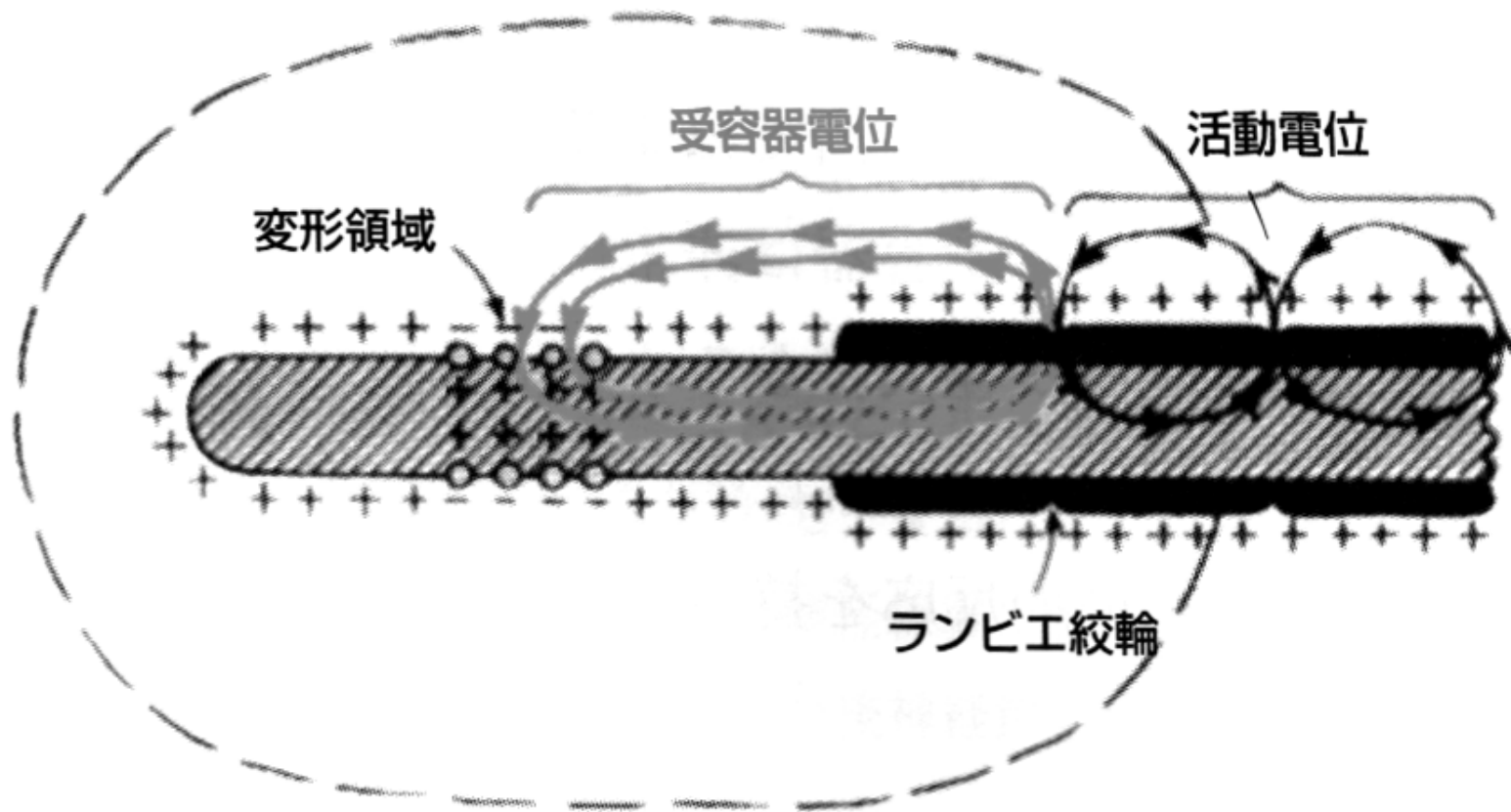


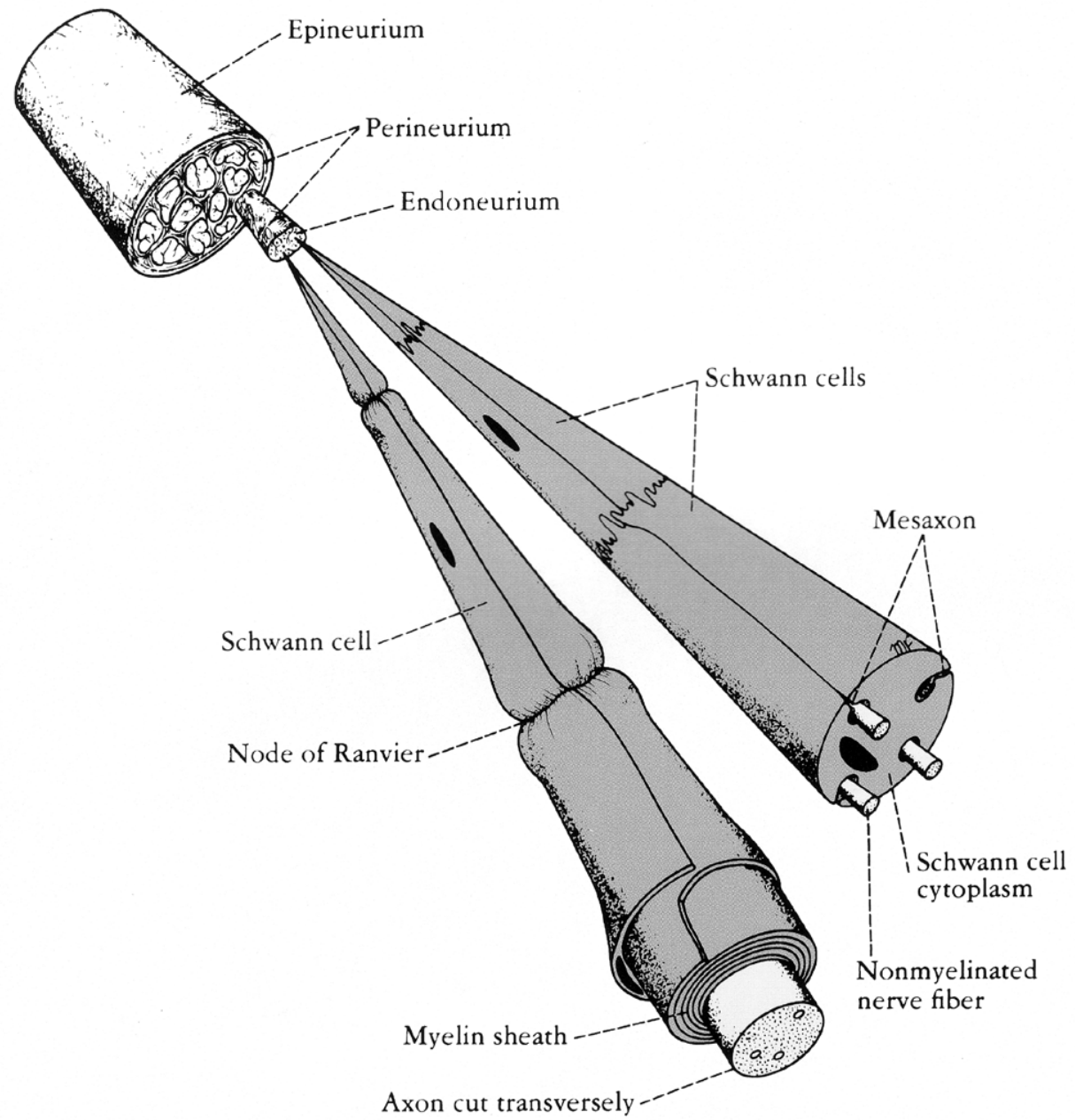
ゴルジ腱器官



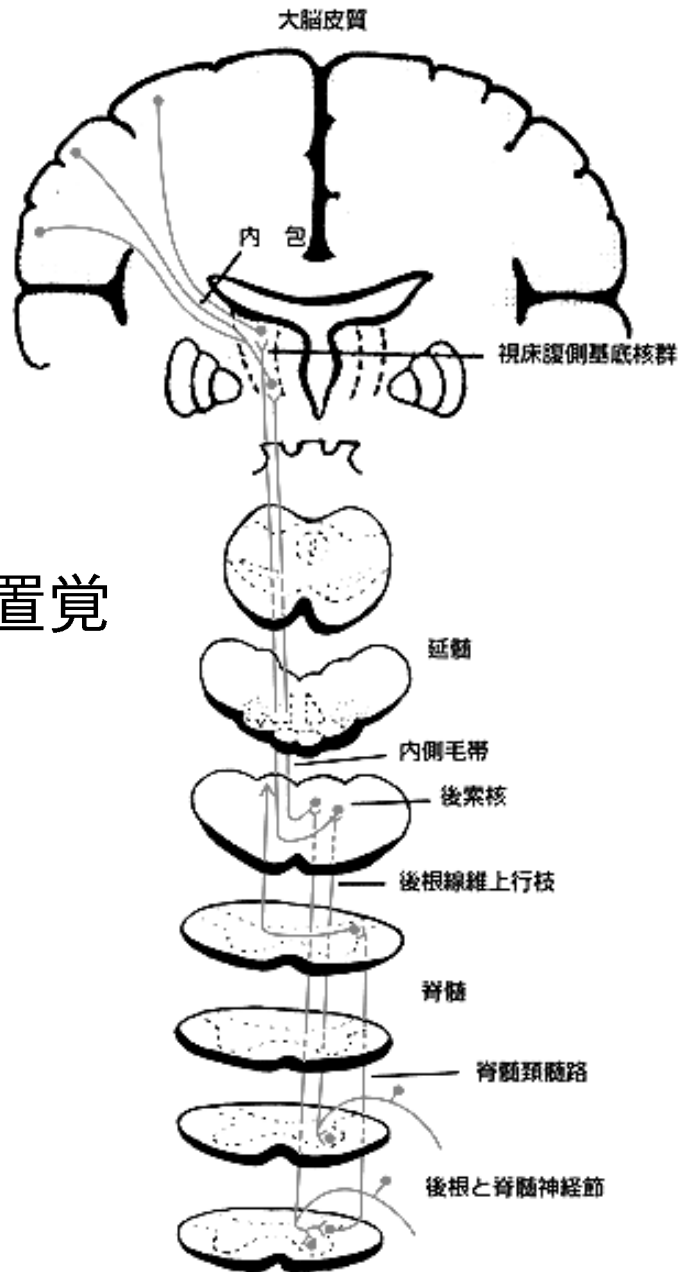
筋紡錘



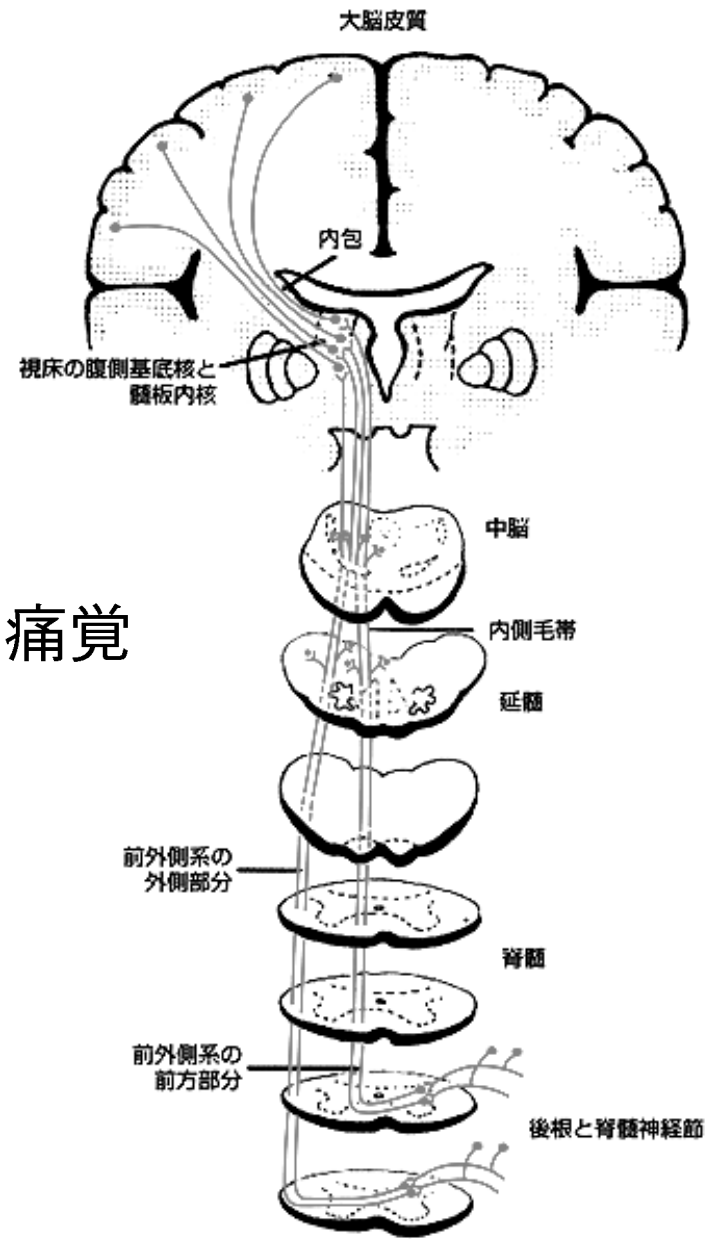


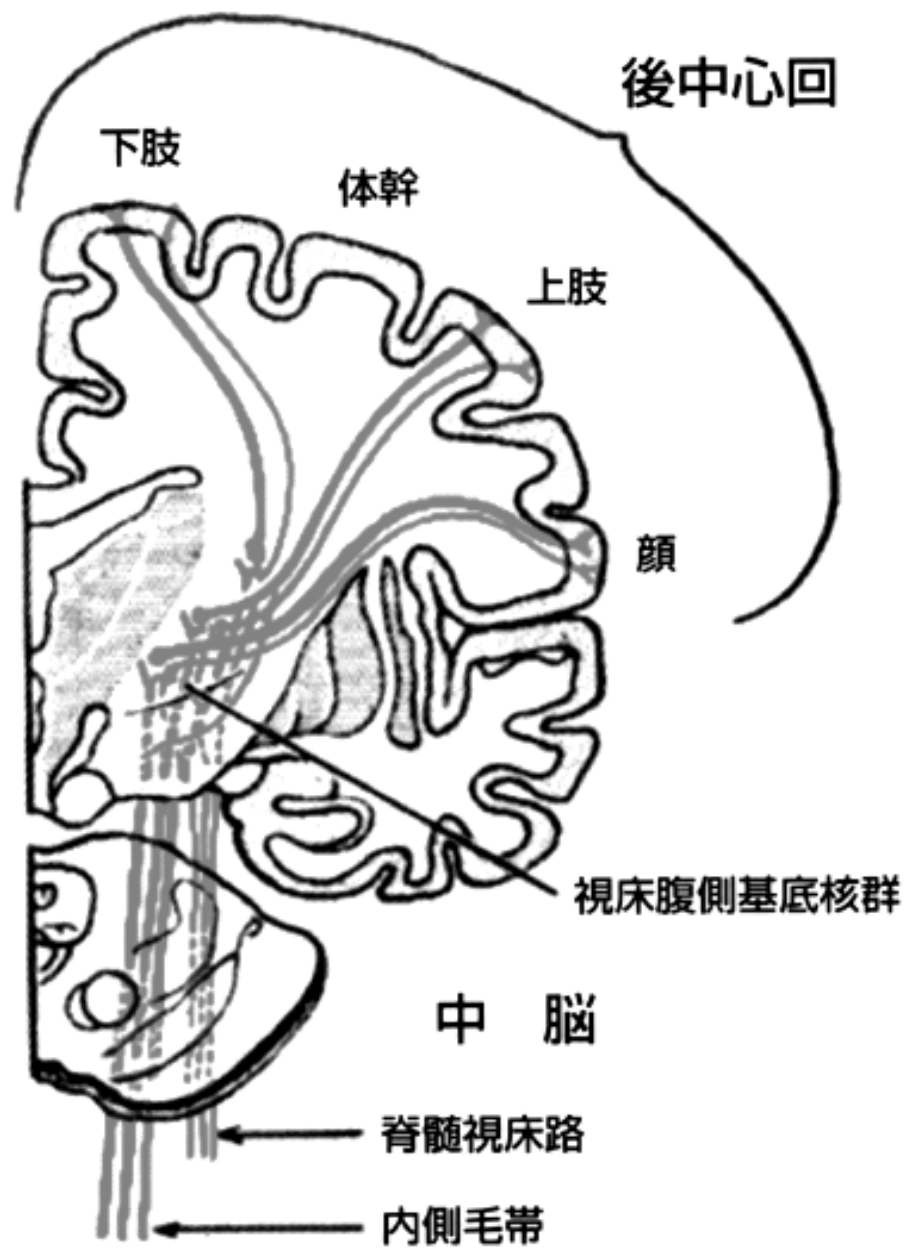


関節位置覚
振動覚

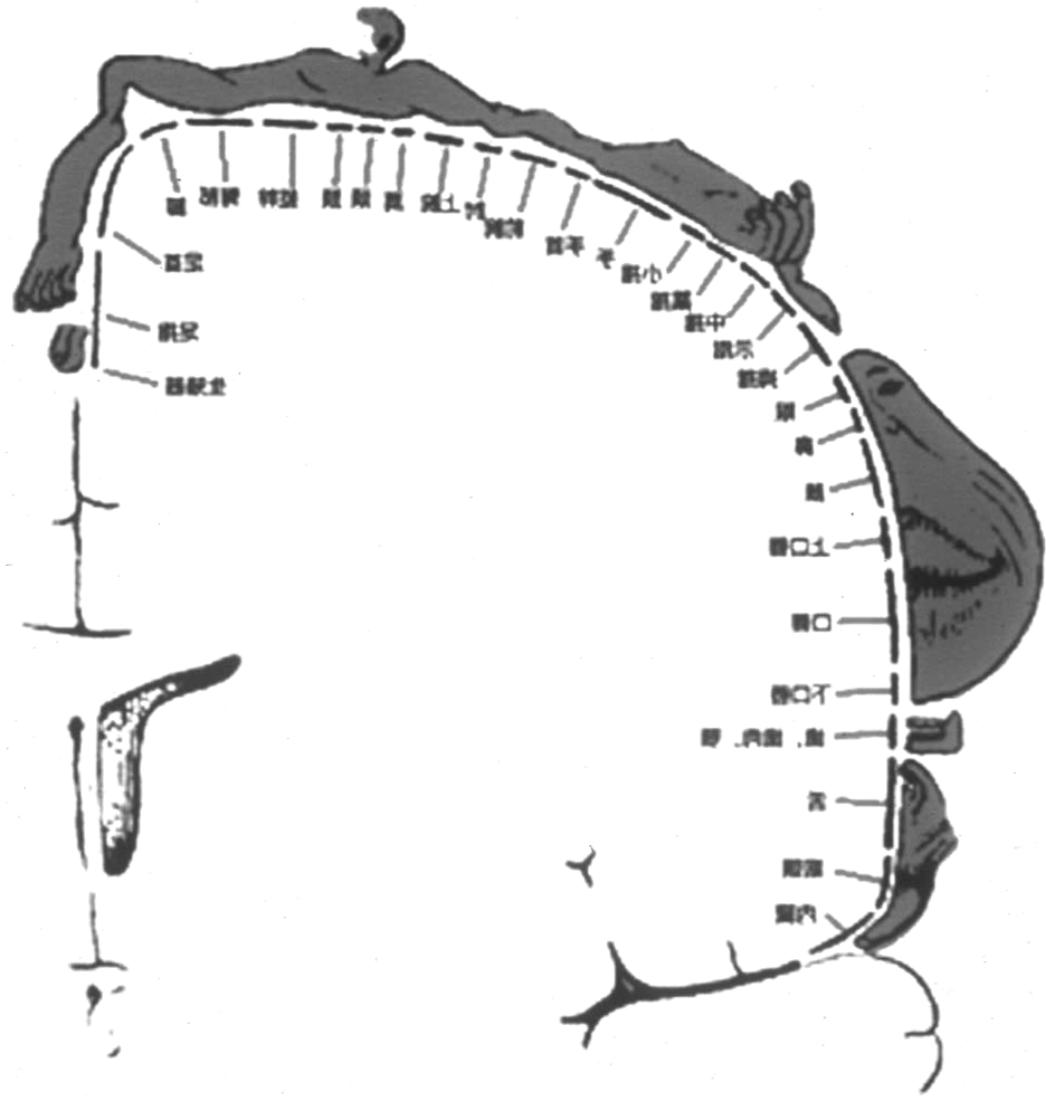


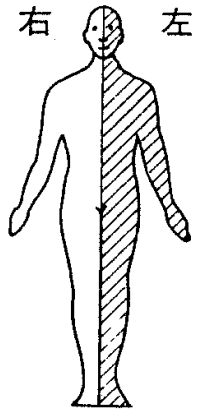
痛覚



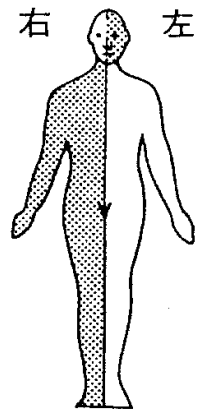


脳の小人—感覚系

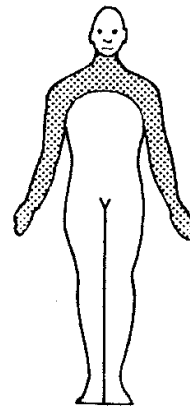




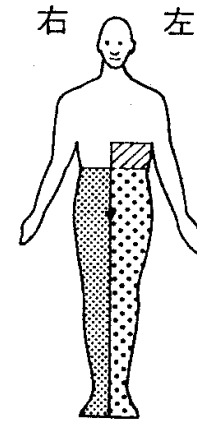
右大脳半球(内包・視床)障害



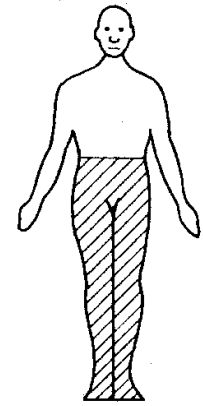
左延髄外側部障害
(Wallenberg 症候群)



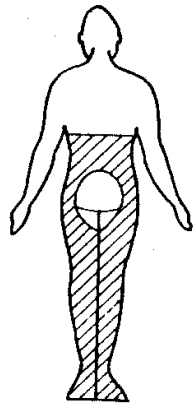
頸髄灰白質部障害
(脊髓空洞症候群)



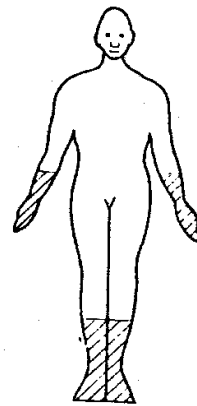
左胸髄半側障害
(Brown-Sequard 症候群)



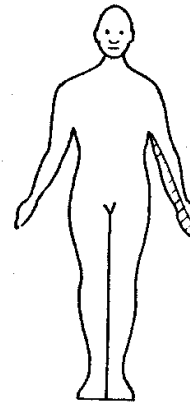
完全脊髓横断障害



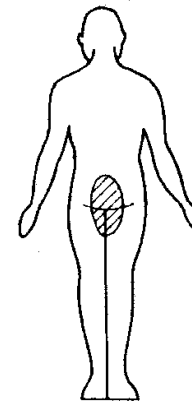
胸髄髄内腫瘍
(sacral sparing あり)



多発神経炎
(左右対称)



左頸部神経根障害



馬尾神経障害

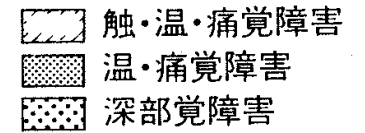
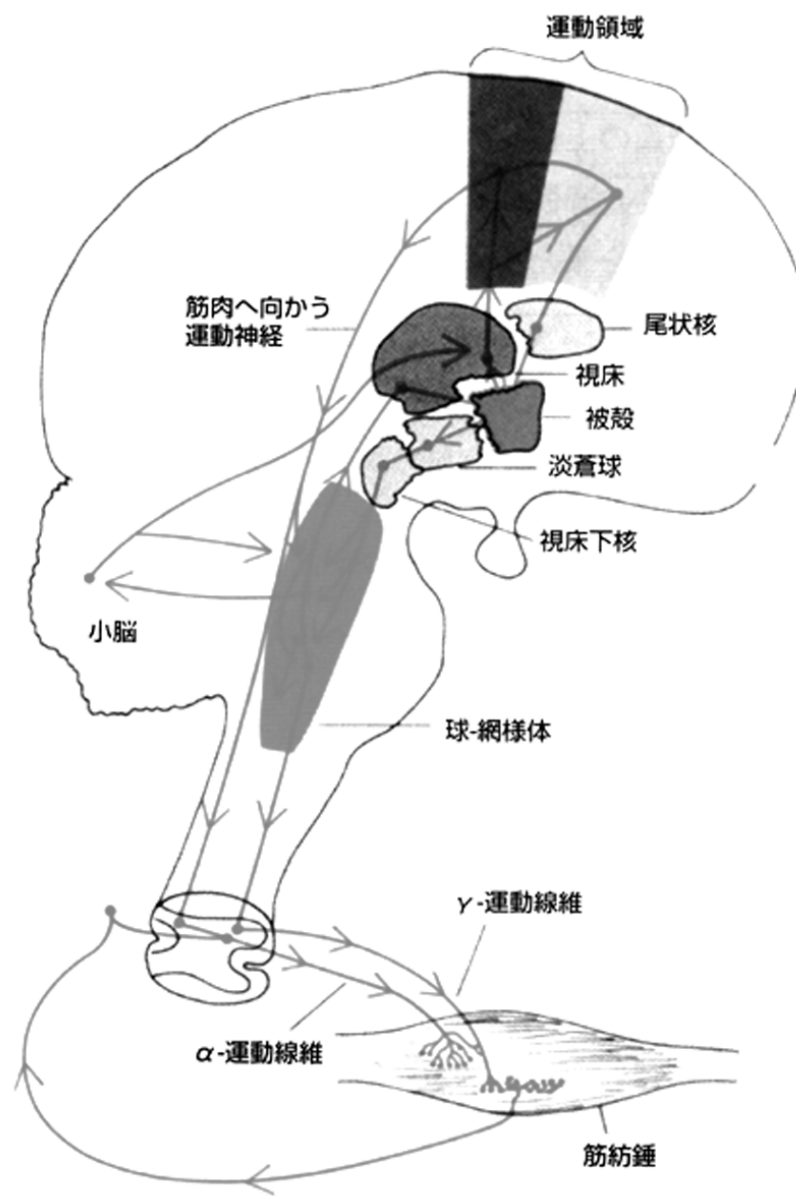
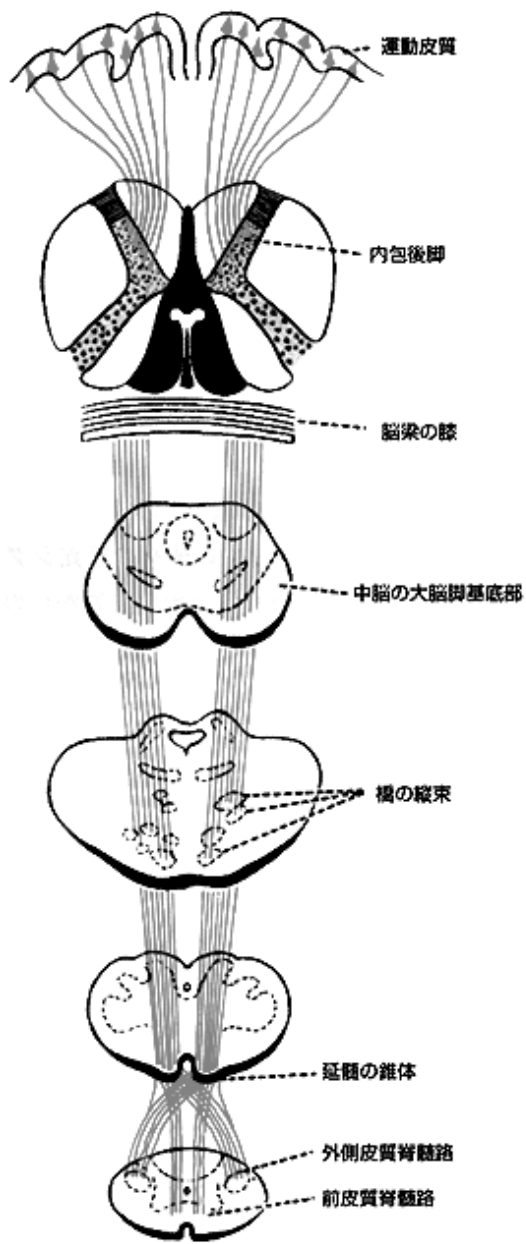
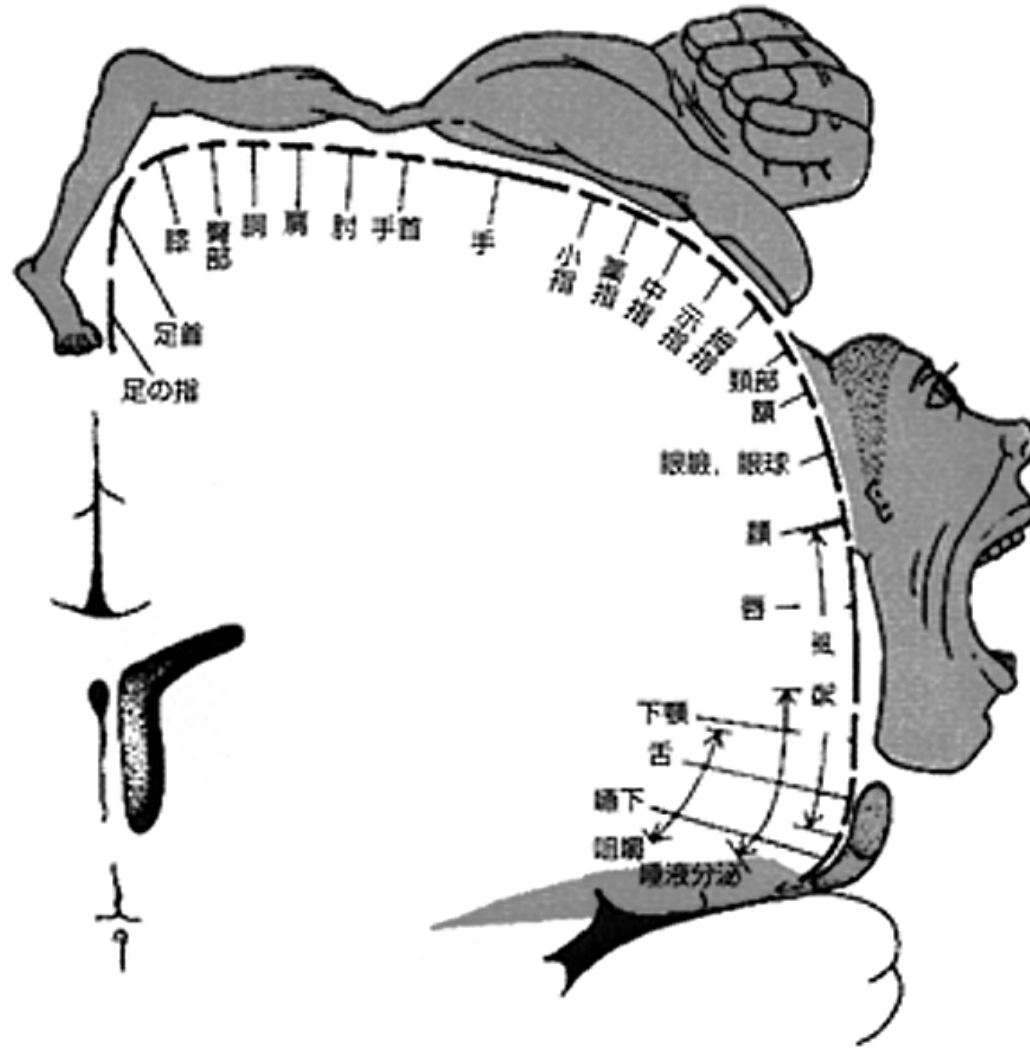


図 176. 感覚障害の型と障害部位

運動系



脳の小人－運動系



大腦皮質
運動野障害

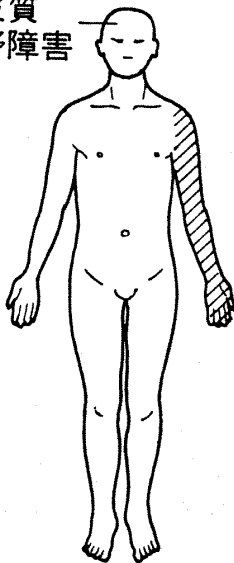


图 67-1. 单麻痺

内包障害

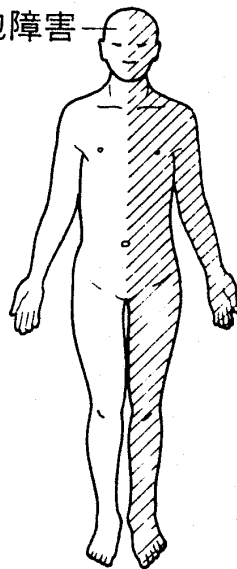


图 67-2. 片麻痺

内包部などの錐体路障害

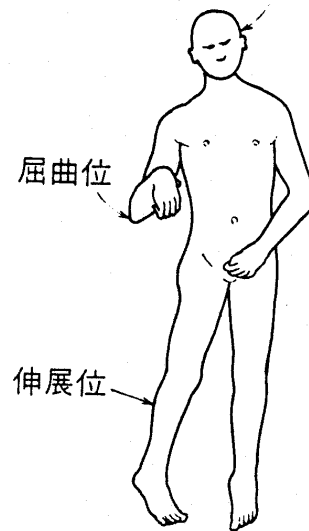

图 68. Wernicke-Mann 肢位

脳幹障害

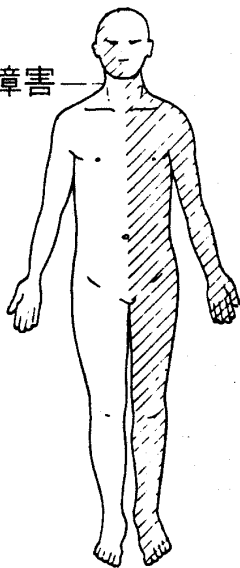


图 67-3. 交代性片麻痺

延髓交叉部
障害

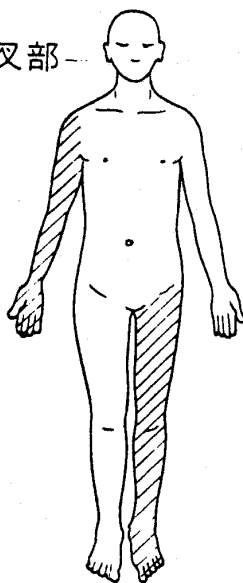


图 67-4. 交叉性片麻痺

頸髓障害

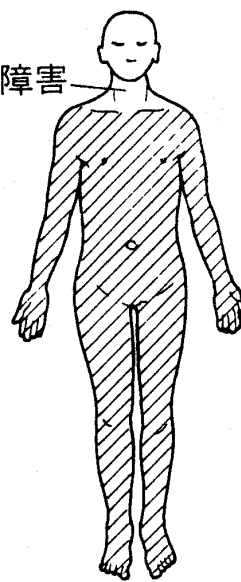


图 67-5. 四肢麻痺

胸・腰髓
障害

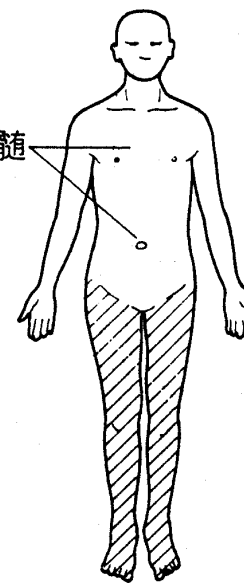
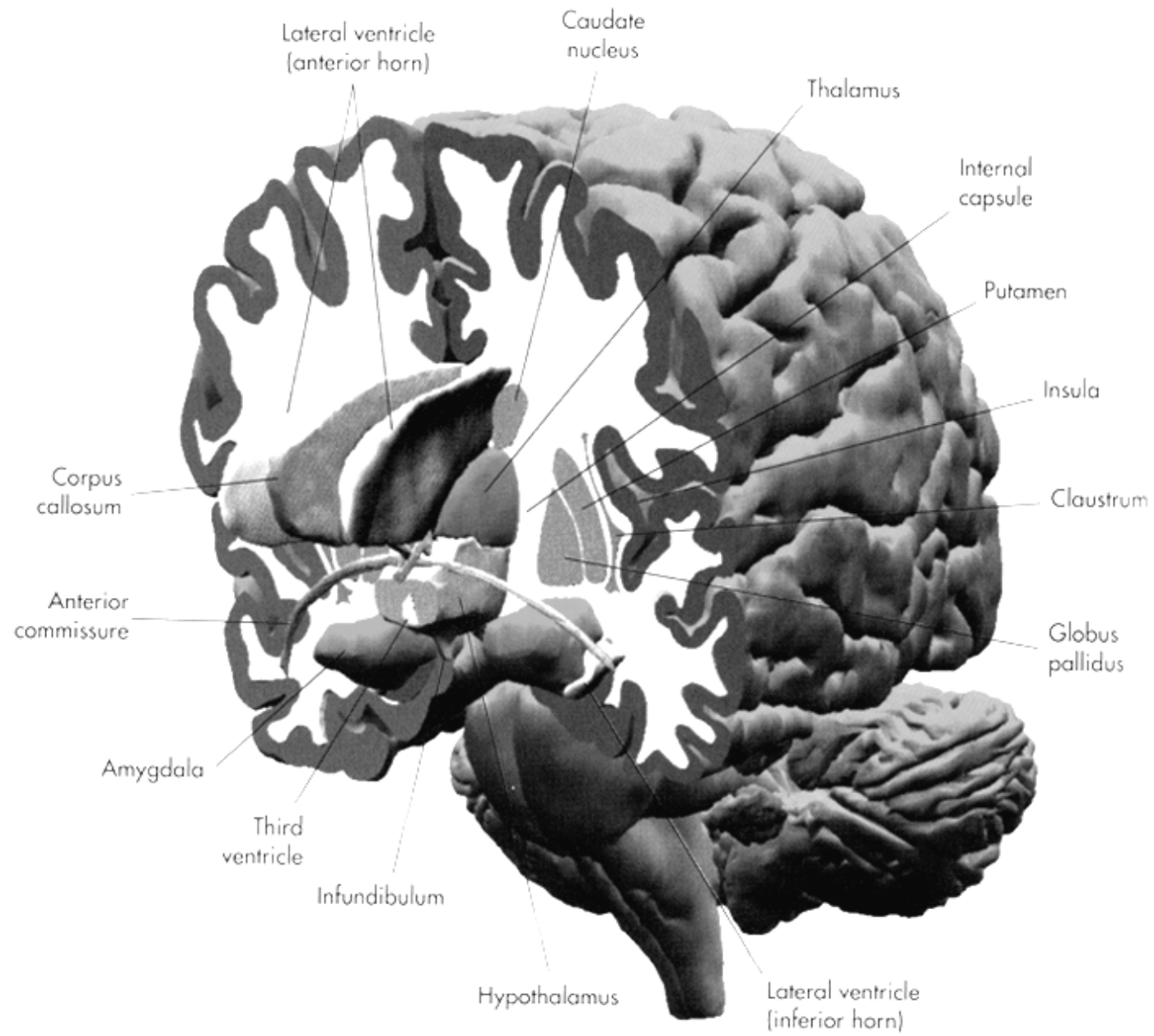
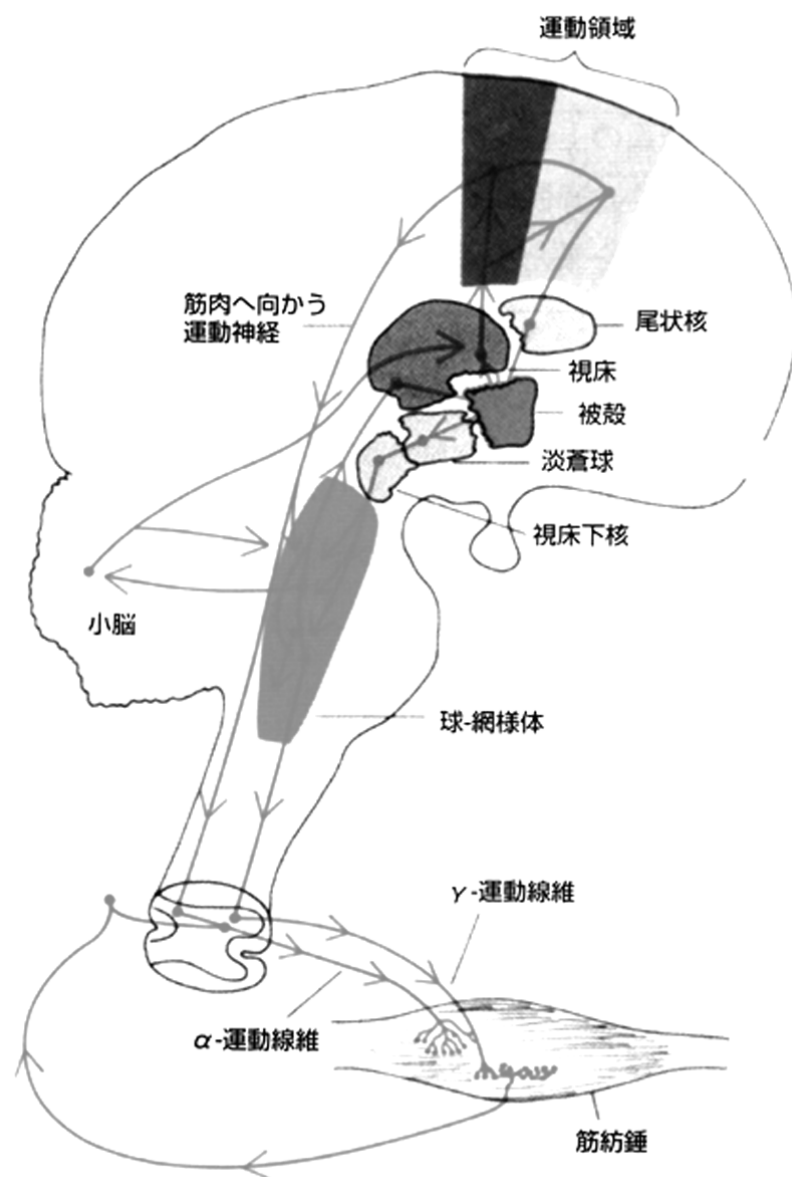
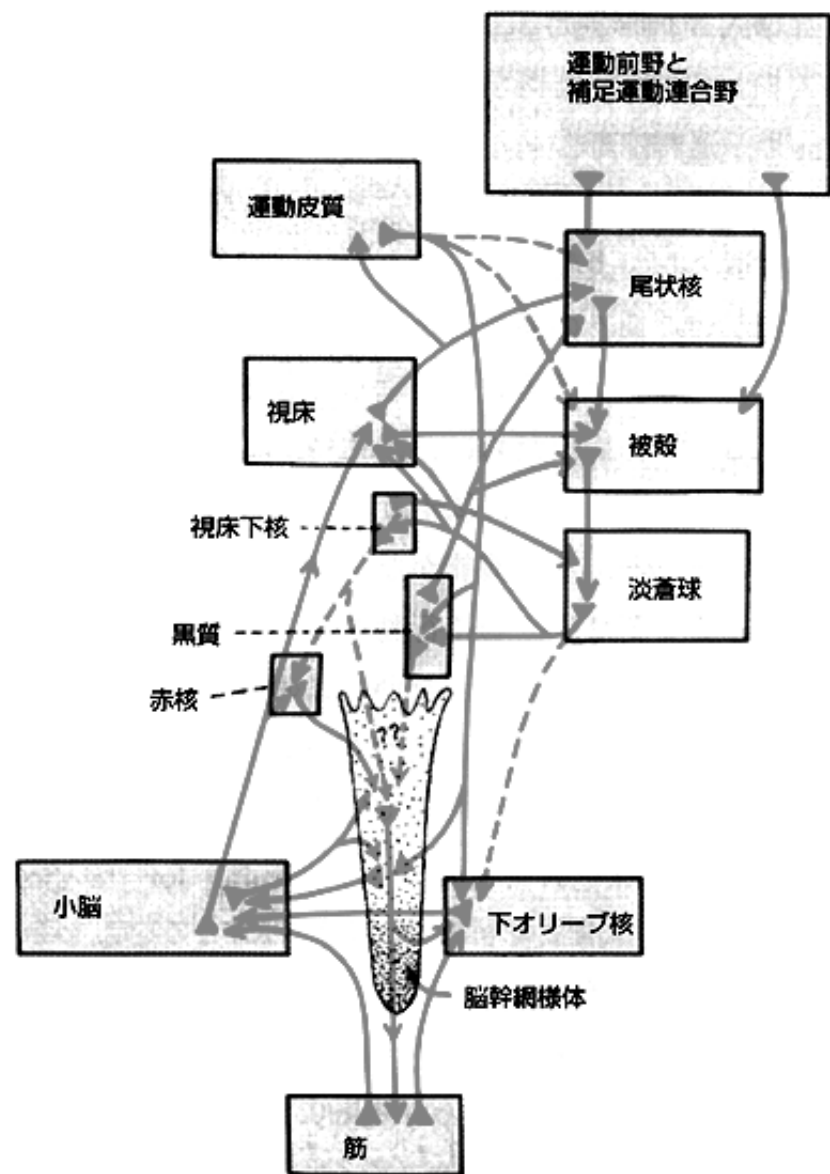
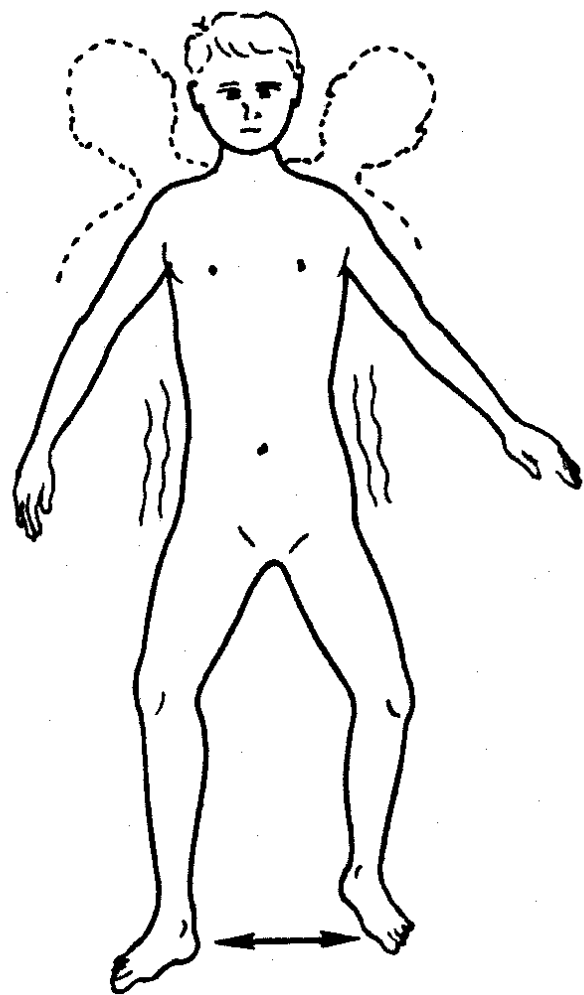


图 67-6. 对麻痺







wide-based gait

(酩酊性・蹠跗性歩行)

図 135. 失調性歩行

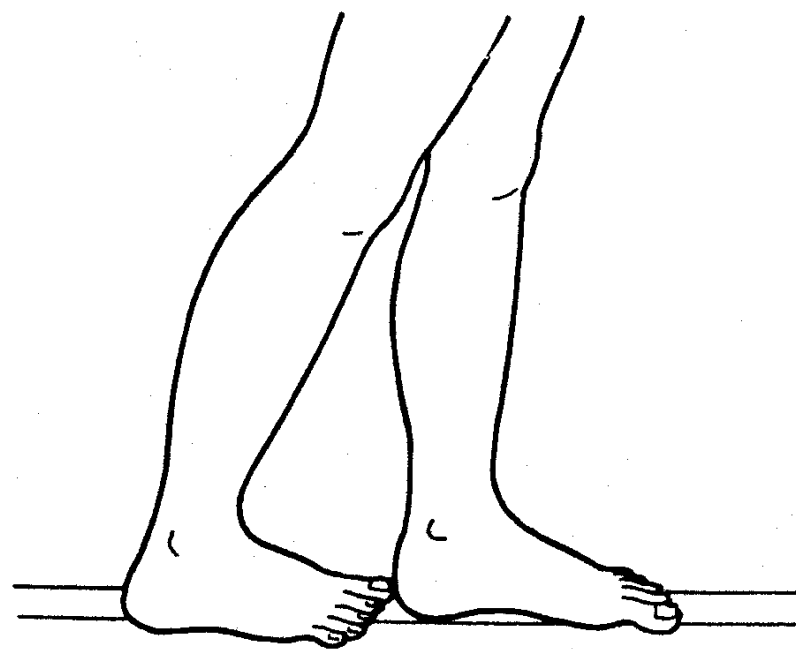


図 120. つぎ足歩行

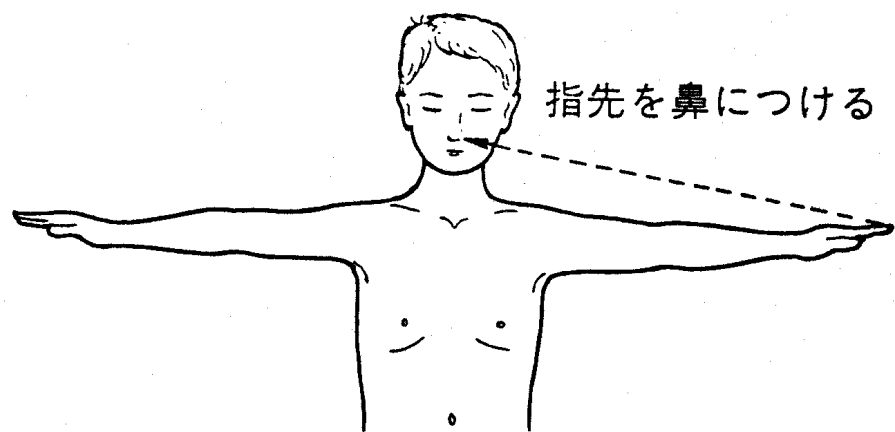


図 117. 指鼻試験

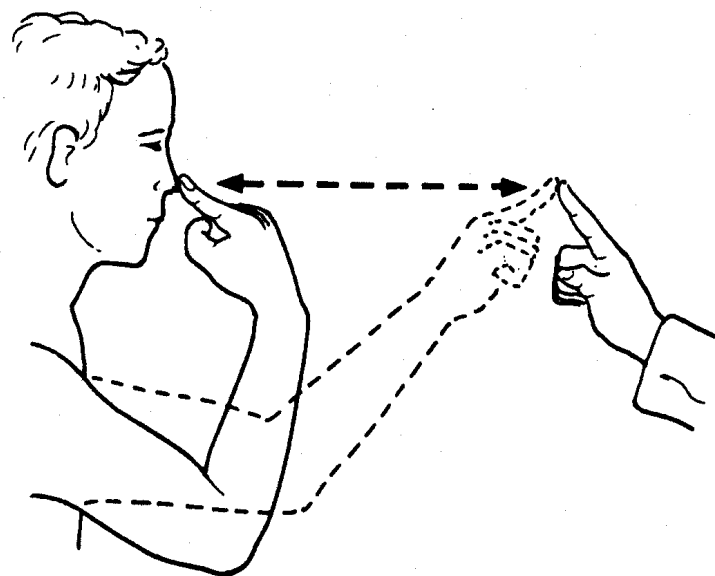


図 118. 鼻指鼻試験

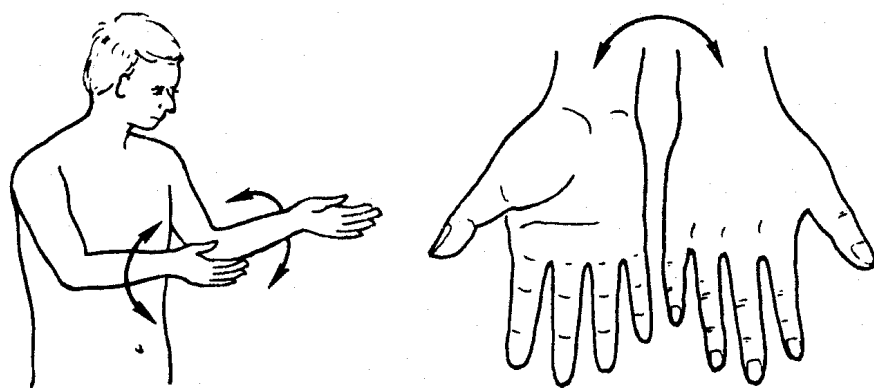


図 124. 拮抗運動反復試験

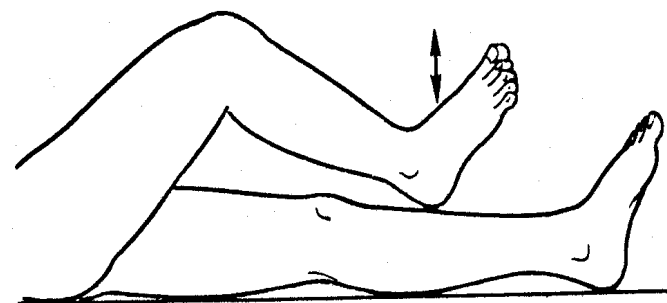


図 125. 脛叩き試験 (shin tapping test)

大脳基底核

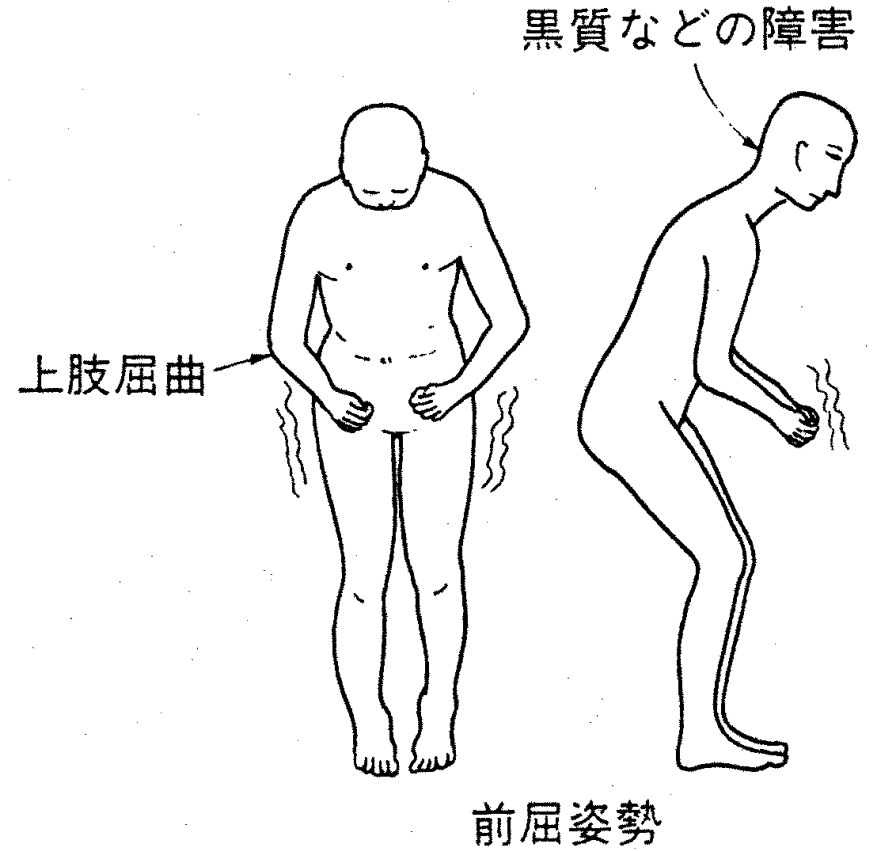
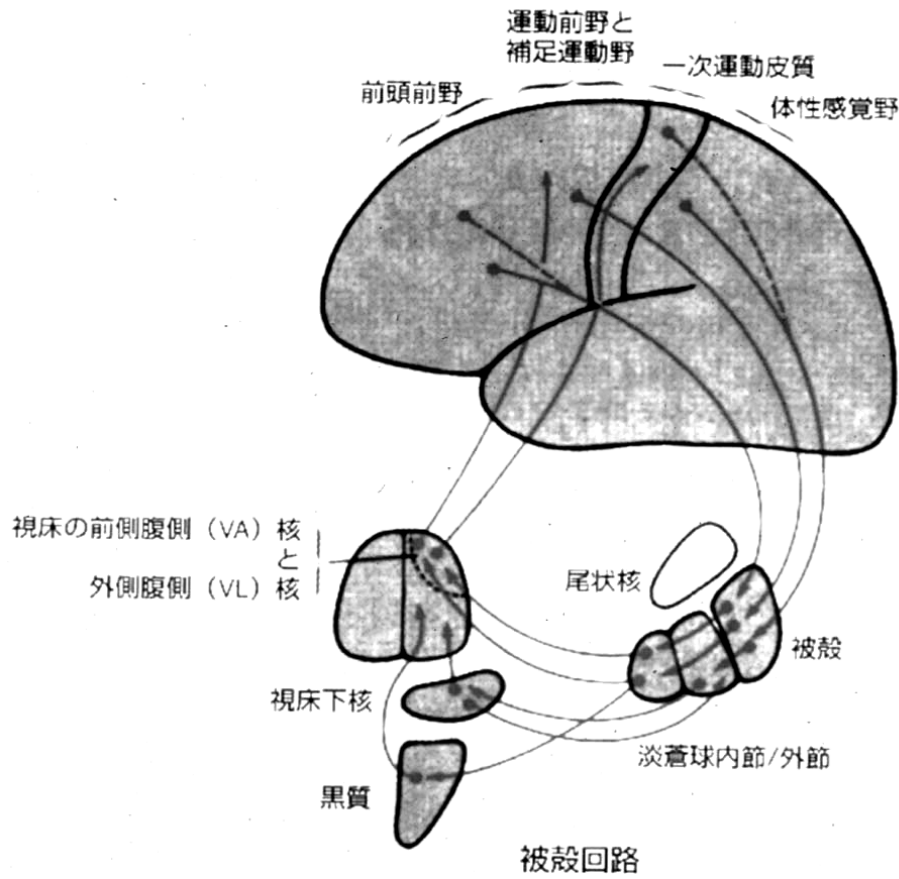


図 71. Parkinson 症候群肢位

